

Immediate rehabilitation of the edentulous mandible with four rigidly bar-splinted implants in a patient with rheumatoid arthritis: A case report

A promising treatment option

Dr Peter Gehrke¹, Oliver Fackler, MDT², and Professor Günter Dhom^{1,3}

The dental rehabilitation of a patient diagnosed with rheumatoid arthritis and a failing dentition using a removable implant-supported prosthesis in the mandible requires a carefully planned and well-sequenced treatment. The report presents a reliable surgical and prosthodontic protocol for immediate loading of implants, allowing the patient to receive an implant bar-supported prosthesis in a matter of hours. It is possible to reduce the treatment time by immediate functional loading of dental implants and immediately placing a bar-supported prosthesis.

The replacement of missing teeth with endosseous implants for rehabilitating edentulous or partially edentulous patients has become standard. To achieve and maintain osseointegration, indications and contraindications must be carefully balanced, and proper patient selection is a key issue in treatment planning. Systemic disorders may affect oral tissues by increasing their susceptibility to other diseases or by interfering with healing. In addition, systemic conditions may be treated with medications or other therapies that potentially affect implants and the tissues supporting them.

Several authors have identified diseases in the presence of which dental implants are not recommended or at least questionable [25-30]. Rheumatic disorders are such a systemic risk factor for implant therapy. It often remains unclear on what type of evidence such statements are based. Recent case reports disprove the suggestion that subjects with rheumatoid arthritis tend to have higher failure rates [31-33].

Historically, the initial considerations in implant dentistry have claimed that the process of osseointegration requires on average three months of undisturbed healing in the mandible and six months in the maxilla [1,2]. An initial two-week period without any removable prosthesis was recommended in edentulous patients. This inconvenient prospect of prolonged treatment often keeps patients with general medical risk factors from seeking implant treatment. On the other hand, edentulism is often associated with functional and esthetic burdens for the patient and is related to psychological problems possibly influencing daily activities. Tooth loss can deeply affect patients' psycho-social well-being, even for patients who seem to adjust reasonably well to a conventional denture [3].

A recent review has concluded that oral condition seems to have a negative impact on the quality of life of fully edentulous patients [4]. Psychological and emotional factors play a major role in patients who are badly adjusted to the treatment performed. Patient satisfaction with immediate loading protocols has been described in a prospective study on mandibular overdentures. It demonstrated a significant improvement of their oral health status compared to their previous conventional denture [5].

There is increasing interest in early and immediate loading of implants to expedite the restorative outcome. *Donath* et al. reported that a load exerted at the implant interface may interfere with bone healing and result in fibrous encapsulation [6]. However, clinical and animal trials have shown that long-term success can be achieved with removable and fixed prostheses on immediately loaded dental implants [7-12]. In addition, initial implant mobility does not inevitably prevent osseointegration.

Micromotion at the implant interface generally has to be distinguished from uncontrolled masticatory forces. The peri-implant bone adjusts its architecture according to its capacity to withstand functional loading. Consequently, the strains induced by these loads affect bone remodelling. It has been suggested that the magnitude of the load transmitted from the implant to the bone determines success [13]. One key to the success of titanium implants thus seems to be successful remodelling at the periphery of the implant.

Microstrain may be a favourable stimulus during the healing period of implants, resulting in increased bone density [14,15]. According to *Brunski* et al., implants can be loaded early or immediately, if micro-

¹ Private practice, Ludwigshafen, Germany

² Dental laboratory, Viernheim, Germany

³ Professor of Management of Dental and Oral Medicine, Steinbeis-University, Berlin, Germany

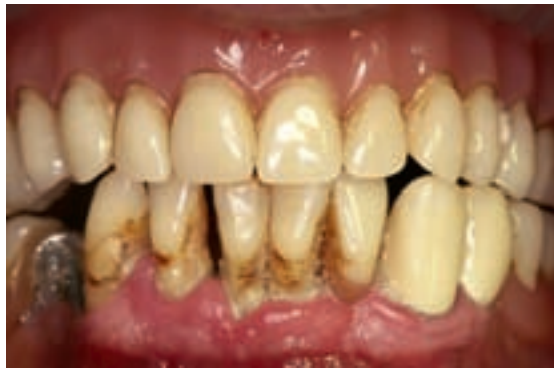

Fig. 1 Facial view of the initial clinical situation and insufficient oral hygiene. Hopeless mandibular dentition and an edentulous maxillary arch with complete denture.

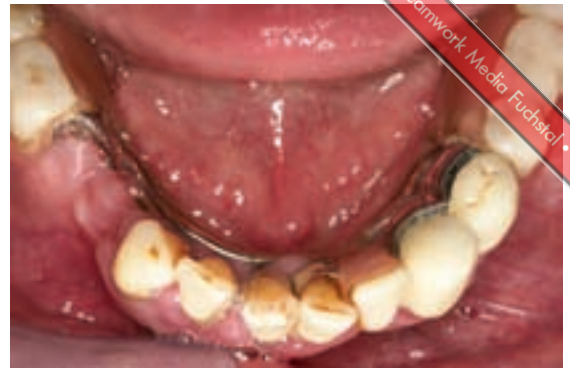

Fig. 2 Occlusal view of residual mandibular anterior dentition and removable partial denture in situ.

movements above 100 μm can be avoided during healing [16]. Stronger movements would lead to soft-tissue ingrowth at the interface rather than the desired bone apposition. Cameron et al. reported that osseointegration can be achieved even in the presence of micromovements, but not in the presence of macromovements [17].

Despite the lack of a consistent terminology on the definition of micro- and macromovements, it has been suggested that a movement of 30 μm or less has no adverse effect on integration, while a movement of 150 μm or more results in connective-tissue apposition to the implant [18-20]. Here it can no longer be assumed that immediate loading per se leads to the fibrous encapsulation of implants. Rigid splinting seems to have a significant impact on the peri-implant tissue response, since it is able to reduce the mechanical stress exerted on each implant. If rigidity is lost, implant failure is likely to occur due to uncontrolled masticatory forces. Consequently, the stability of the restoration and the ability to keep the micromovements below the critical threshold are considerably increased by rigid splinting.

The classical prosthetic concepts for immediate loading of implants in the edentulous mandible involve bar-supported overdentures in the mandible. High predictability of immediate loading of rigidly bar-splinted implants in healthy patients has been shown in several reports [21-24]. As demonstrated by Ledermann and Chiapasco, four interforaminal implants rigidly connected with a U-shaped bar can reduce macromovements and lead to survival rates similar to delayed loading protocols. The existing literature supports loading of microroughened implants splinted by a bar construction within 48 hours. A successful, accelerated protocol for implant rehabilitation depends upon several interactive factors: Beside the patients' medical health status, accurate presurgical diagnostics and treatment planning, implant macro- and microdesign, the adequate fixation and

immobility of the implant are of utmost importance to prevent the risk of movements related to the surrounding bone. Clinically oriented protocols for immediate function of implants should consider a sufficient number of implants for primary splinting; appropriate implant length of at least 10 mm; absolute primary stability of implants at insertion; rigid, primary splinting of the implants with the superstructure to avoid uncontrolled macromovements; and anterior-posterior implant distribution to avoid rotation.

This clinical report describes the treatment and two-year prosthetic follow-up of a patient with rheumatoid arthritis, treated with four implants and a bar-supported restoration with immediate functional loading in the mandible.

Materials and methods

A 62-year-old non-smoking male patient diagnosed with rheumatoid arthritis presented with a hopeless mandibular dentition and an edentulous maxillary arch (Figs. 1 and 2). The regular application of cytostatic drugs in combination with poor oral hygiene had led to progressive periodontitis (Fig. 3).

Due to the specific systemic condition and the patient's request for a minimal surgical and restorative intervention, an implant procedure with immediate loading was proposed for the mandibular arch.

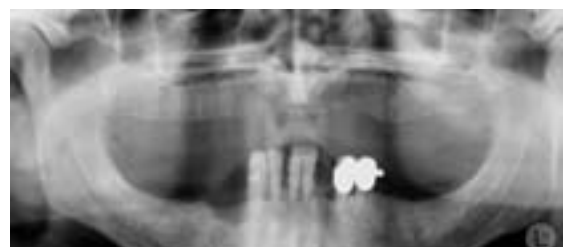

Fig. 3 Initial panoramic x-ray. Regular application of cytostatic drugs and poor oral hygiene had led to a progressive periodontitis and mobility of residual mandibular teeth.

All compromised mandibular teeth were extracted twelve weeks before implant placement, and the sockets were carefully debrided (Fig. 4). Complete maxillary and mandibular prostheses were fabricated according to the conventional procedure (Figs. 5 and 6). The patient was seen continuously for oral hygiene instructions and evaluated preoperatively with respect to mandibular size, bone quantity, interarch relationship and maxillomandibular distance (Fig. 7). Preoperative analysis of anatomic structures was performed with panoramic radiography. The patient started antibiotic therapy the day before surgery (2 g/d of amoxicillin). Local anaesthesia (2% articaine/adrenaline 1:100,000) was administered prior to surgery. Surgery considered a crestal incision that ran from the region of the right to the left second premolar (Fig. 8). A full-thickness buccal flap was raised, exposing the anterior mandible, and the mental foramina were located (Figs. 9 and 10). After flap reflection and location of the mental

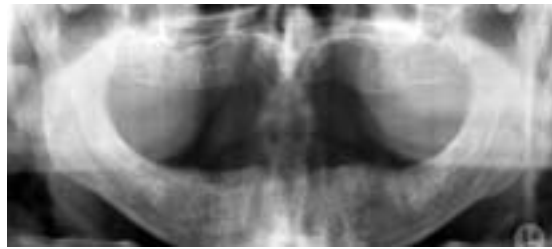
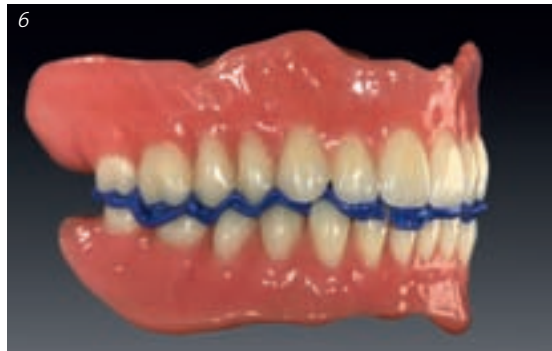
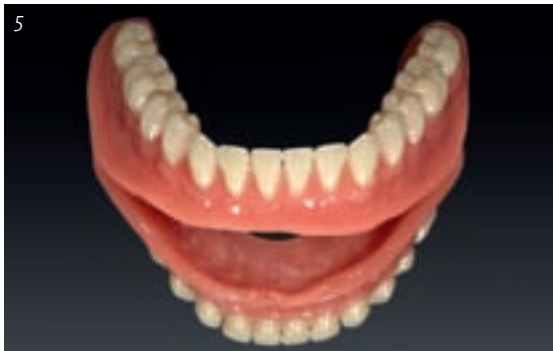
Fig. 4 All compromised, residual mandibular teeth were extracted and sockets were carefully debrided twelve weeks before implant placement.

foramina, the length of the mental nerve loop and the shape of the bone were assessed using an atraumatic instrument in order to determine the ideal angulation of the posterior implants. A mild osteoplasty of the ridge was performed under profuse irrigation with sterile saline solution (Fig. 11). An acrylic denture copy was used as a drilling guide (Fig. 12).

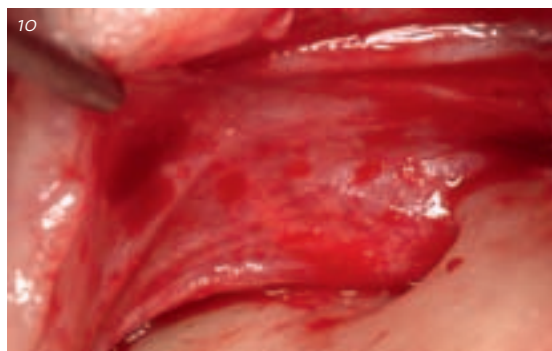
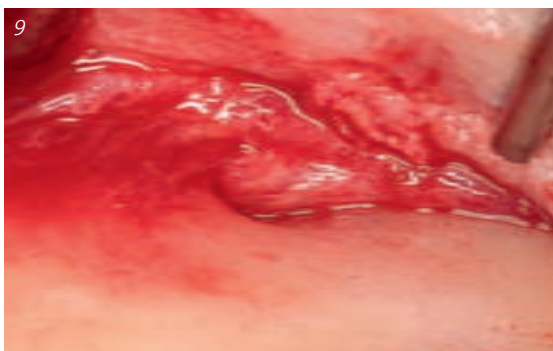


Figs. 5 and 6 Complete maxillary and mandibular prostheses have been fabricated according to the conventional procedure.

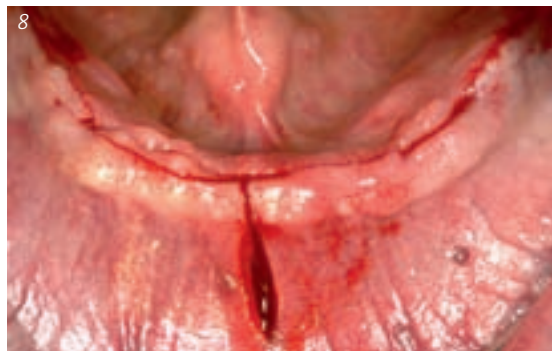
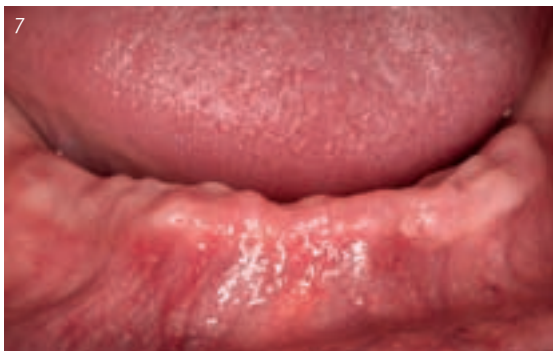
Fig. 7 Clinical situation twelve weeks after tooth extraction.

Fig. 8 Crestal mandibular incision from region of right to left second premolar.



Figs. 9 and 10 Full-thickness buccal flap and location of mental foramina left and right.

Fig. 11
Mild osteoplasty
of ridge under
profuse irrigation
with sterile
saline solution.

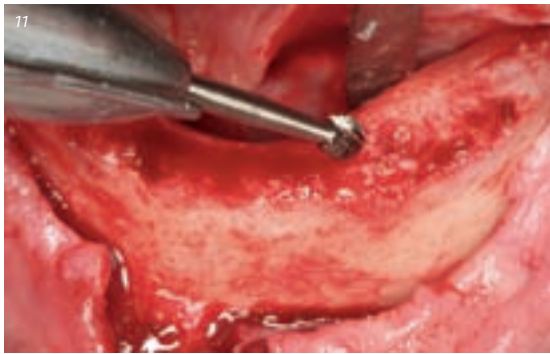


Fig. 12
Acrylic denture
copy utilized as
drilling guide.

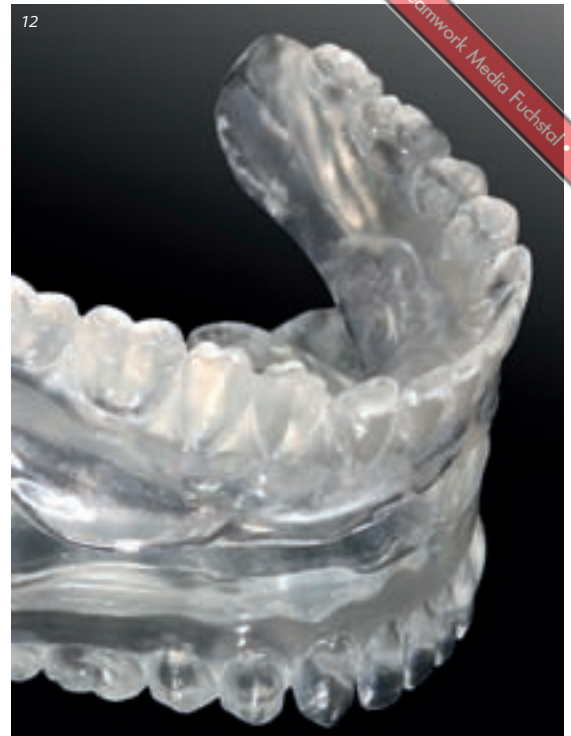
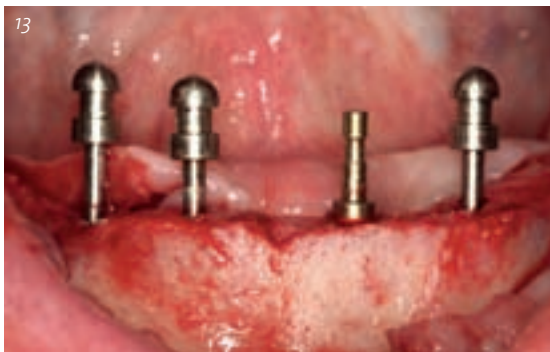
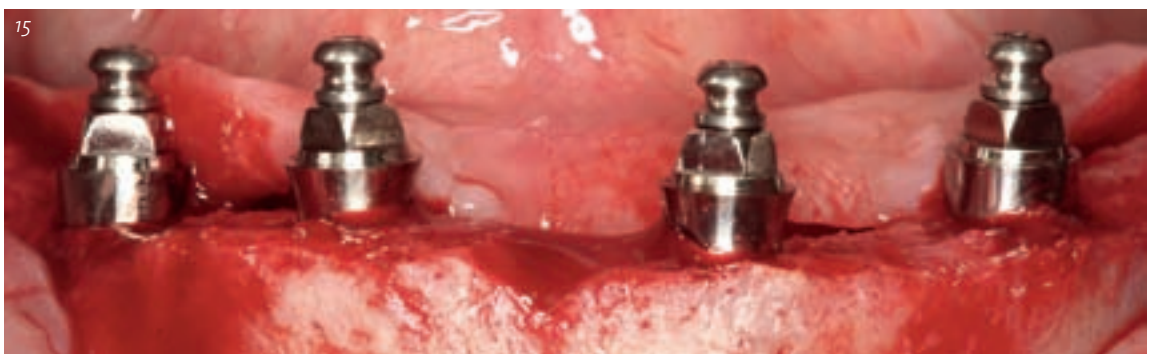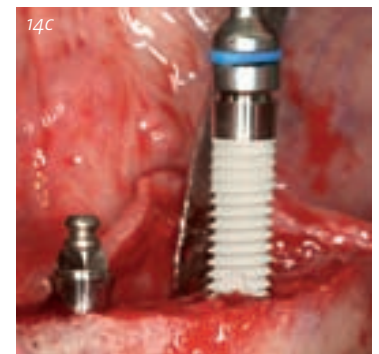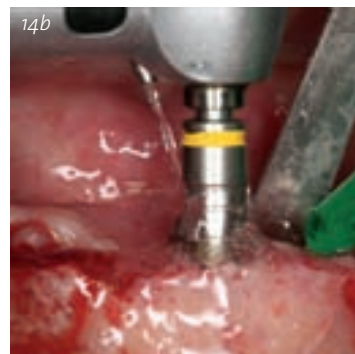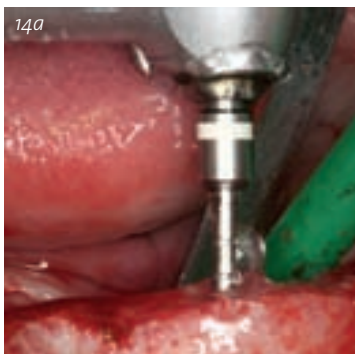Fig. 13
Four implant
sites within the
interforaminal
area. Distal sites
were placed
2 mm mesial to
mental nerve.
Medial sites
equally divided
the remaining
anterior space.



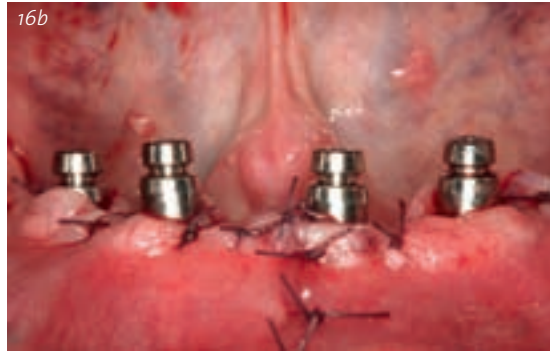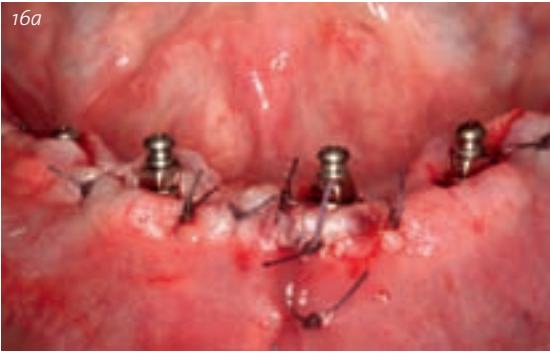
Figs. 14a to 15
Four transgingival
Xive TG screw
implants were
placed in the
interforaminal
area of the
mental symphysis.



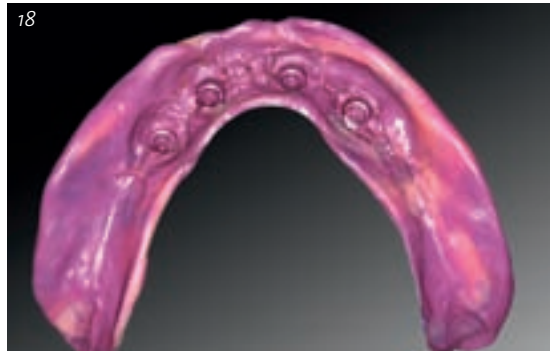
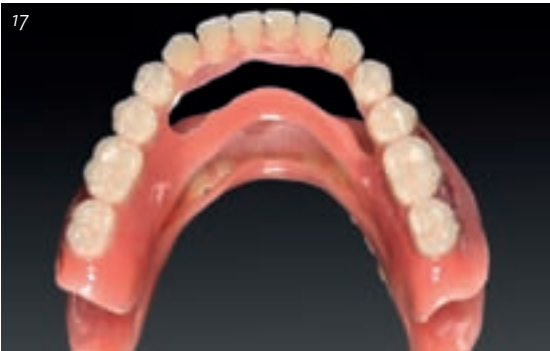Four implant sites were chosen in the interforaminal area, with the distal sites located 2 mm mesial to the mental nerve and the medial sites equally dividing the remaining anterior space (Fig. 13). Subsequently, four grit-blasted and acid-etched transgingival screw implants were placed in the interforaminal area of the mental symphysis (Xive TG, Dentsply Friadent, Mannheim, Germany) (Figs. 14a to 15).

High primary stability is required for immediate function of implants and immediate restoration. In our experience, the specific implant thread design and a site preparation mode that takes bone quality into due account achieve internal condensation of the peri-implant hard tissue even in cancellous bone.

After attaching impression copings, the soft tissues were sutured with a 5-0 non-resorbable suture



Figs. 16a and b
After attaching
impression
copings, the
soft tissues
were sutured.

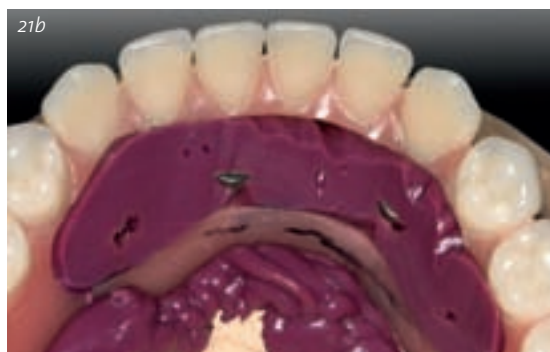


Figs. 17 and 18
Impression taking:
Silicon medium
body material by
using newly
fabricated lower
denture as
impression tray.

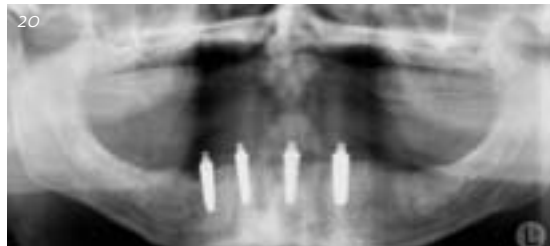
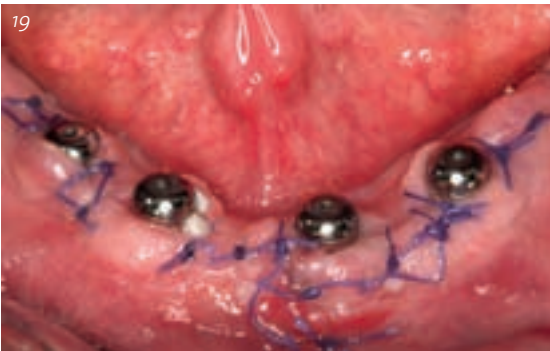
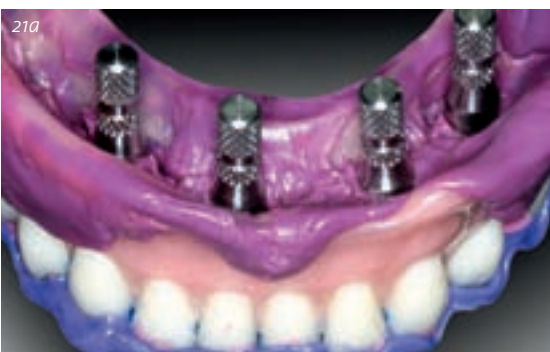Fig. 19
Healing caps
positioned over
the implants
while the
patient was
dismissed for a
couple of hours.

Fig. 20 Panoramic x-ray after implant placement.

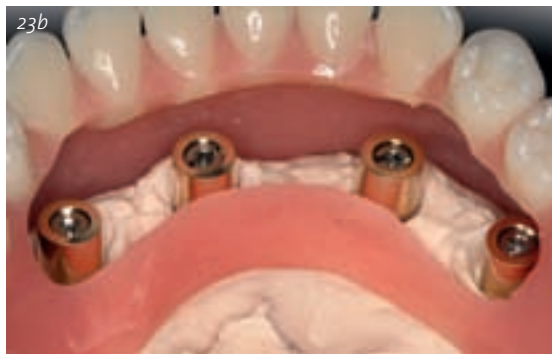
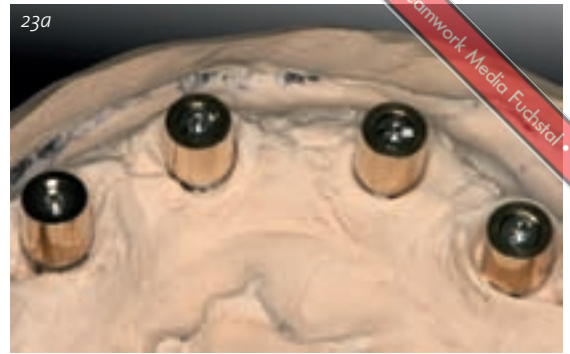
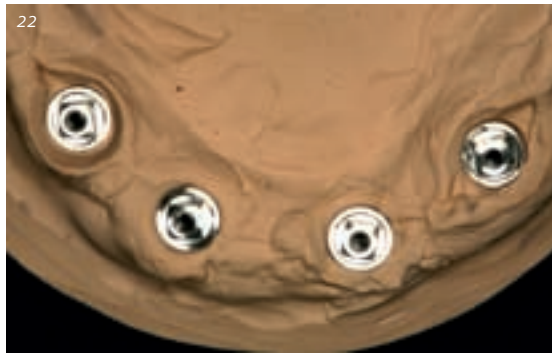


Figs. 21a and b
Assembly of lab
implant copings
and prearrange-
ment for pouring
the master cast.

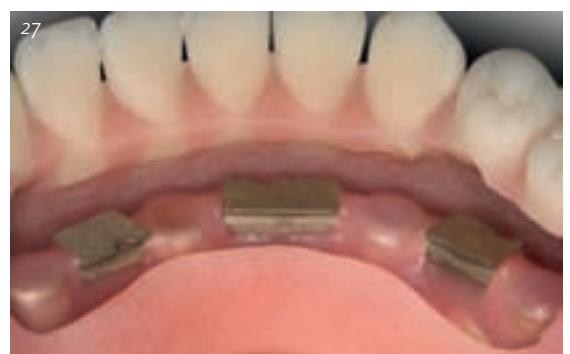(Vicryl, Johnson & Johnson Intl., Neuss, Germany) (Figs. 16a and b). An impression was taken at the gingiva level by means of a silicon medium-body material (Aquasil Ultra, Dentsply DeTrey, Konstanz, Germany) for the fabrication of a mesio-bar superstructure. The impression was taken with the newly fabricated

mandibular denture serving as an impression tray (Figs. 17 and 18). The occlusion was checked at the same time. Healing caps were positioned over the implants, and the patient was dismissed for a couple of hours (Figs. 19 and 20). The impression was poured and a master cast was fabricated (Figs. 21a and b).

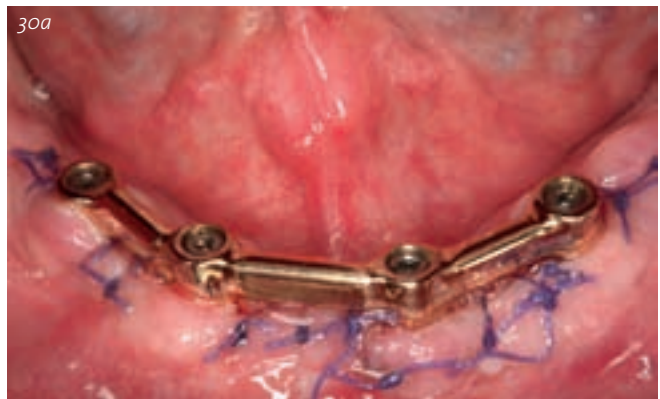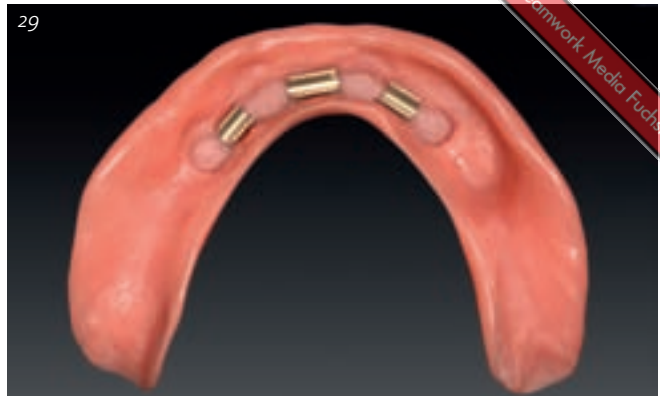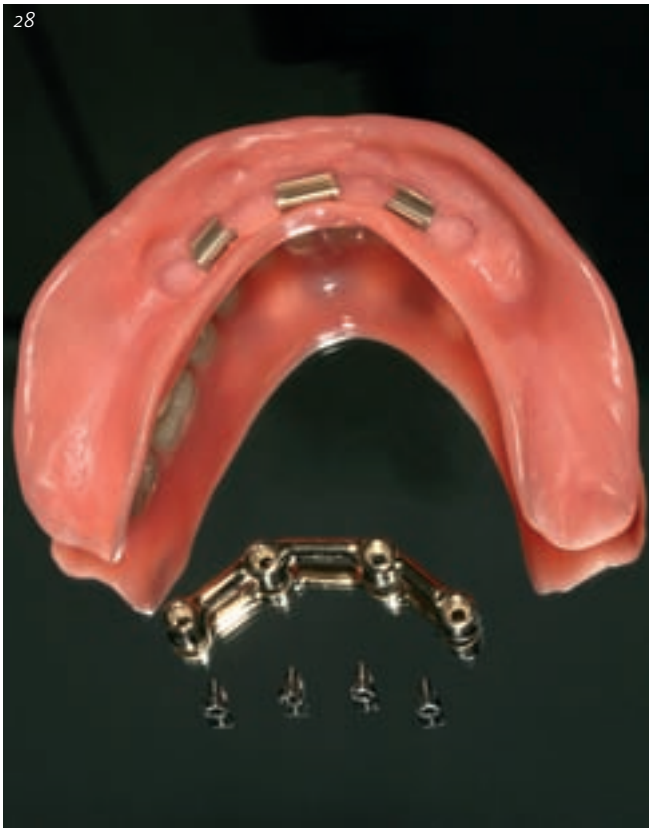
*Figs. 22 to 25
Prefabricated
round gold bars
and bar copings
were soldered
(Xive TG Gold Bar
Coping).*



*Figs. 26 and 27
A U-shaped gold
bar was fabricated
and bar-clips
were polymerized
into the
overdenture.*



Prefabricated round gold bars and bar copings with a cross-section of 2 mm were soldered (Xive TG Gold Bar Coping, Friadent Gold Bar round, Dentsply Friadent, Mannheim, Germany) (Figs. 22 to 25). A U-shaped gold bar was fabricated, and bar-clips were polymerized into the overdenture (Figs. 26 and 27).



Figs. 28 to 30a Delivery of bar restoration and overdenture eight hours after surgery.

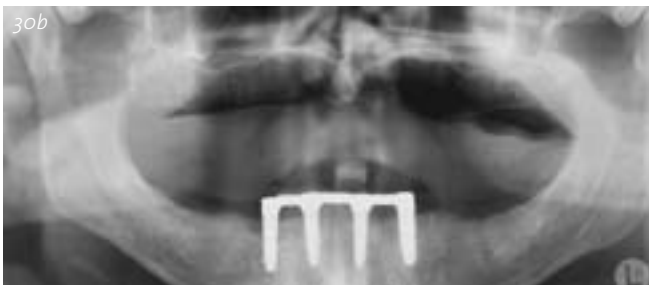

Fig. 30b Panoramic radiograph: Check of implant positions and coupling between prosthetic components.

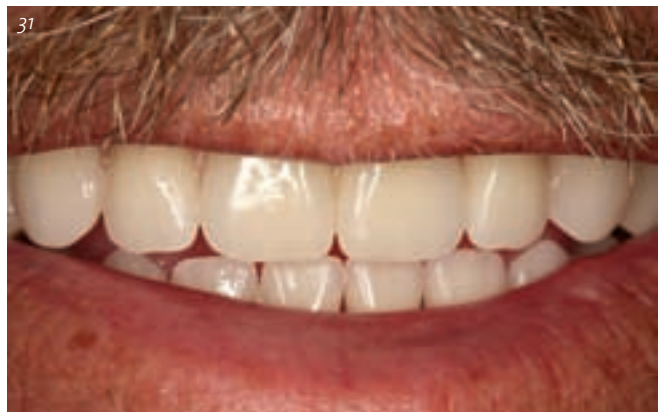

Fig. 31 Facial view of final restoration. Immediate loading of four rigidly bar-splinted implants in the mandible with a complete removable prosthesis.

The bar-supported restoration and corresponding clip attachments in the overdenture were delivered eight hours after surgery (Figs. 28 to 30a). A panoramic radiograph was taken to check the implant positions and the coupling between the prosthetic components (Fig. 30b). The patient maintained a soft diet for four weeks after surgery. Oral hygiene instructions were provided. During the first month after surgery, the patient was seen once a week for control visits evaluating tissue healing and prosthetic function. Eight days after surgery, the patient was scheduled for suture removal. Further control visits

were scheduled at six, twelve and 24 months. The patient was monitored at close intervals for oral hygiene prophylaxis. Figure 31 shows a facial view of the final restoration.

Results

Compared with traditional implant protocols, this protocol of a one-day approach for patient treatment

- 1) decreases the number of office visits,
- 2) decreases the treatment time,
- 3) reduces the patients' costs,

4) enhances patient comfort and the ability to masticate within a few hours after implant placement, and
5) increases the patients' acceptance of treatment while maintaining predictability in treating mandibular edentulism in case of rheumatic disorders.

Discussion

Recent clinical reports have demonstrated good surgical and restorative success rates for patients suffering from rheumatic disorders [32]. Within implant dentistry, a tendency can be observed to reduce treatment time. This is done to simplify procedures with the purpose of increasing patient tolerance and reducing the probability of complications. Initial studies of immediate loading, with a primary goal of a direct bone-implant contact, have been proposed for overdentures in completely edentulous but otherwise healthy patients. These studies have shown encouraging results. In 1997, *Chiapasco* et al. reported on 226 consecutive patients with mandibular overdentures with 904 implants inserted between the mental foraminae and an average of 6.4 years of function with 96.9 per cent implant survival [10]. More recent reports by *Gatti* and *Chiapasco* et al. on overdentures have continued to demonstrate implant survival rates above 96 per cent [34,24]. In general, patients with completely edentulous mandibles restored with overdentures are at the lowest risk of occlusal overload for immediate loading protocols. To this date, maxillary overdentures have not been adequately addressed in the literature.

Conclusion

Although the progression of systemic disorders is unpredictable, good implant and prosthodontic success rates can be expected even in patients suffering from autoimmune rheumatic disorders. A strict maintenance and control program that includes optimal oral hygiene helps ensure stable long-term results. In this context, an immediately placed, occlusally loaded complete removable prosthesis supported by four rigidly bar-splinted implants does not jeopardize osseointegration and represents a viable treatment. ■

A list of references can be found on www.teamwork-media.de

Contact address

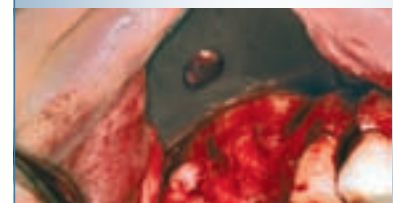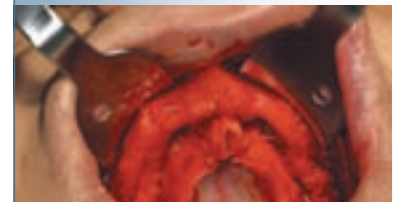Dr Peter Gehrke
Bismarckstraße 27 · 67059 Ludwigshafen · Germany
Phone: +49 621 68124444
dr-gehrke@prof-dhom.de



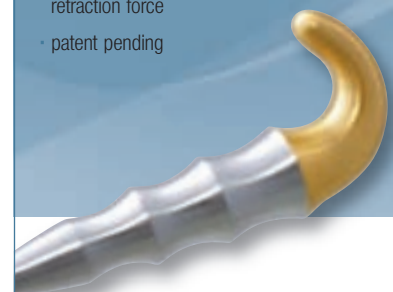
SINUS RETRACTORS

ACC. TO PROF. (NYU) DR. MED. DENT.
MANFRED LANG

Clinical Associate Professor
Department of Implant Dentistry, New York University



- retraction of the mucoperiosteal flap during lateral sinus window preparation
- mucoseal flap is secured by the "shark-teeth"
- designed asymmetrically, right and left version
- also suitable for retraction in the anterior region
- anatomical handle ensures only moderate retraction force
- patent pending



Bodenseeallee 14-16
78333 Stockach · Germany
Tel. +49 7771-64999-0
Fax +49 7771-64999-50

www.kohler-medizintechnik.de