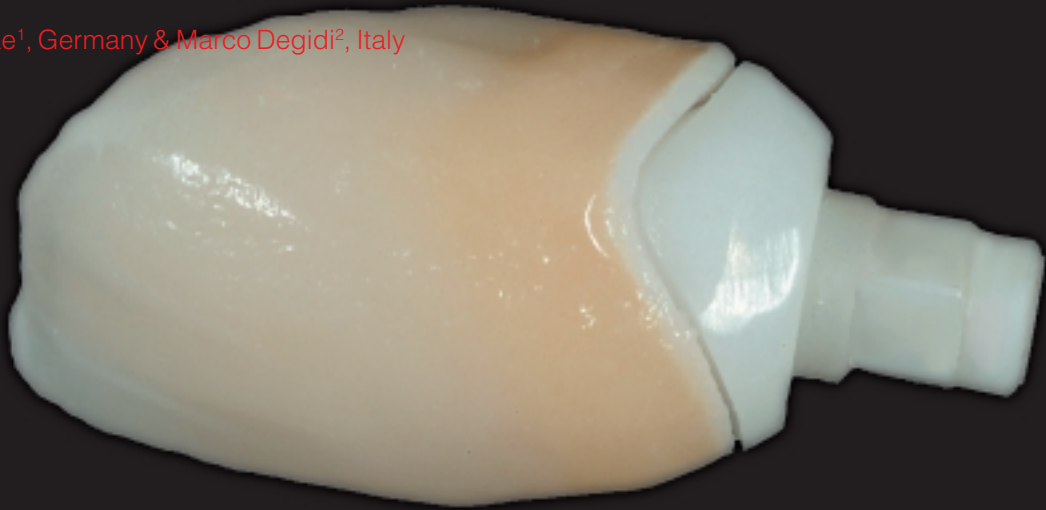


# Facilitation of Full-Ceramic Implant Restorations in the Esthetic Zone: Utilizing Prefabricated Zirconium Copings on Corresponding Implant Abutments

author\_Peter Gehrke<sup>1</sup>, Germany & Marco Degidi<sup>2</sup>, Italy



**Fig. 9** Finalized full-ceramic restoration in the laboratory. Coping served as foundation for porcelain crown.

**An accurate and** systematic approach is required to evaluate, diagnose and resolve esthetic problems predictably. Tooth color is obviously essential for the final result, but esthetic treatment planning should never be focused around shade improvements alone. The ultimate goal is to achieve of a pleasing smile architecture considering the proper proportion and relation according to established principles.<sup>1-4</sup>

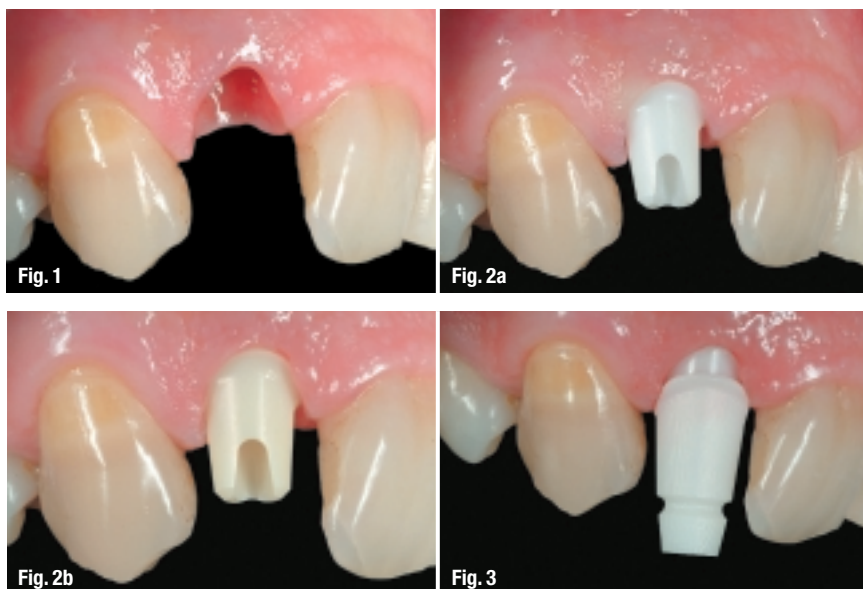
Predictable osseointegration has taken the role of implant dentistry beyond the mere restoration of function for the compromised edentulous case to esthetic single tooth implant supported restorations in the anterior region. Today, implants have become a viable treatment option for partial edentulism. However, to be the preferred treatment choice, the implant supported restoration should, cosmetically, be equal or surpass that of conventional fixed prosthesis. This necessitates developing an implant recipient site in both hard and soft tissue for optimal placement of the implant and emergence of the restoration.

Implants should not be limited by the osseous to-

pography, which can compromise the final restoration, but implant placement should rather be restoration driven.<sup>5</sup> The increasing predictability and longevity of ceramic implant abutments offer a beneficial asset to cosmetic implant prosthodontics. Implant placement and single-tooth restoration in the "esthetic zone" of the anterior maxilla can present restorative challenges due to high visibility and influence on the facial appearance.

Conventional titanium abutments, for example, can diminish porcelain translucency and often result in a darkened restoration with a bluish, metal shimmer at its margin. This results in a significant loss of esthetic quality and may contribute to an unsatisfactory treatment outcome, particularly for patients with a high smile line and thin soft tissue. A subsequent change in soft-tissue margins often leads to the visibility of titanium at the gingival margin. Although metal implant abutments have inherent esthetic disadvantages, they are most widely considered a standard treatment option for implant supported restorations. The art of looking natural, however, has been perfected by ceramics.

# Immediately loadable KOS implants



**Fig. 1** \_ Labial view after implant osseointegration (right lateral incisor) and stage-two soft tissue healing.

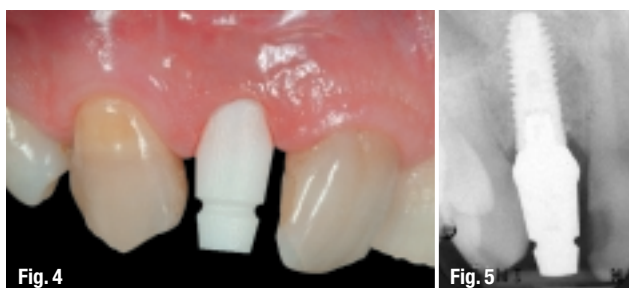**Fig. 2a & b** \_ Try-in of zirconium ceramic abutments available in different shades (Cercon® neutral/Cercon dentin).

**Fig. 3** \_ Seating of Cercon Cap for impression taking.

Their application in restorative dentistry has opened up a new era in esthetic tooth replacement. Improved material characteristics, complying with clinicians' and patients' increased demands for highly esthetic results, have contributed significantly to the development of a new generation of implant abutments made from zirconium-dioxide noted for their tooth-like color, high load strength, tissue tolerability and intra-sulcular design enhancement.<sup>6-14</sup>

Plaque accumulation on implant abutments induces an inflammatory reaction within the gingiva and alveolar mucosa in the same manner as around teeth.<sup>15-17</sup> Bacterial infection has also been reported to be one of the possible reasons for implant failure.<sup>18-21</sup> Peri-implantitis is a site-specific, plaque-induced infection leading to progressive bone loss. Different adhesion affinities of bacteria have been reported for different materials such as titanium, titanium alloy and ceramics. The degree of adhesion between bacteria and abutment depends on the abutment's and bacteria's free surface energy, the roughness of the surface, and the saliva's ionic conductivity. Recent studies by Scarano et al.<sup>22</sup> confirmed a 40% reduction in bacterial adhesion on zirconium-dioxide compared to titanium with comparable roughness. A comparative immunohistochemical evaluation of vascular growth factor, inflammatory infiltrate, proliferative activity expression and micro vessel density in the peri-implant soft tissues surrounding titanium and zirconium-dioxide healing caps revealed statistically decreased values for zirconium-dioxide.<sup>23</sup> Consequently, zirconium actively contributes to peri-implant tissue protection.

This article summarizes a systematic restorative approach using a novel premanufactured zirconium abutment/coping system in partially edentulous patients. The prosthetic and laboratory procedures for an implant supported single tooth replacement in the esthetic region are addressed and illustrated in a step-by-step approach.



**Fig. 4** \_ Cercon Cap fully seated.

**Fig. 5** \_ Periapical X-ray of ZrO<sub>2</sub>-abutment/cap unit on implant.



## Good reasons for switching to Dr. Ihde KOS implants:

- Implant manufactured as a single piece
- Graceful design
- Straight, 15°, 25° angulation or with flexible implant neck
- Minimal-invasive
- Few prosthetic parts, high efficiency
- Favourable price

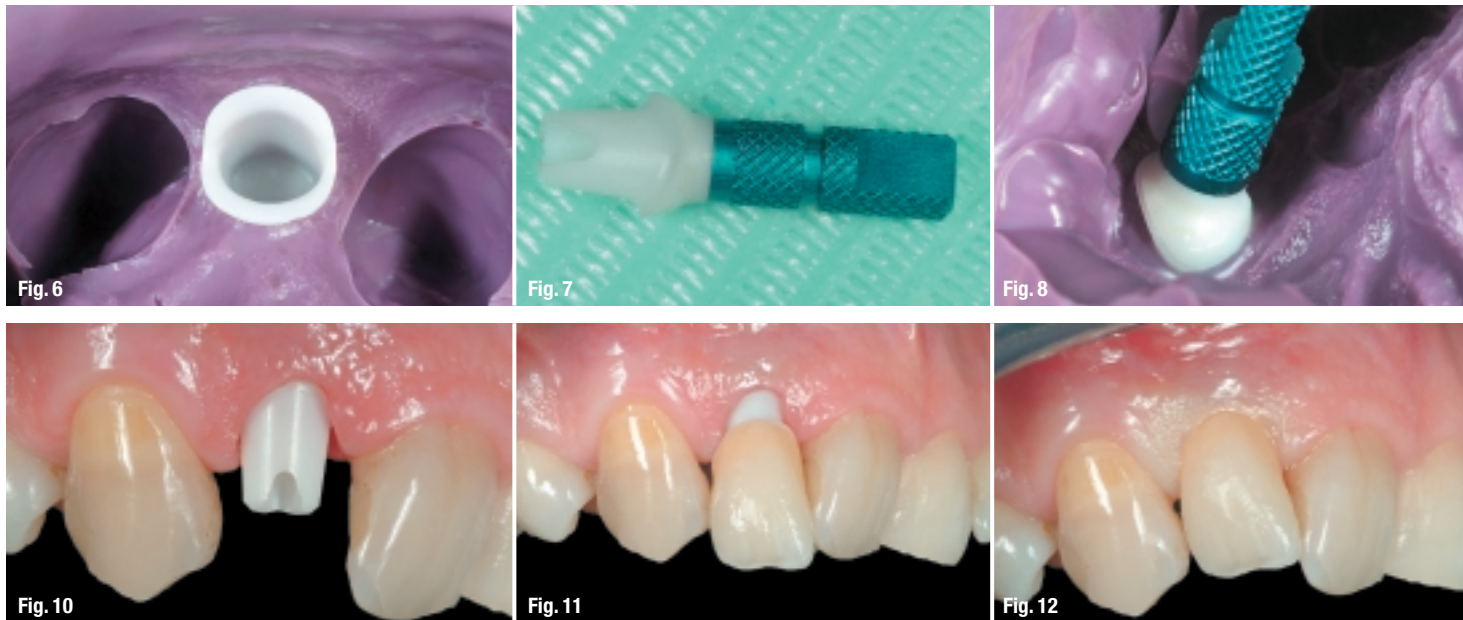
Request more information and catalogue:

**Dr. Ihde Dental**

Erfurter Straße 19  
D-85386 Eching  
Telephone: +49 (0) 89.319761-0  
Fax: +49 (0) 89.319761-33  
E-mail: info@ihde.com

www.implant.com





**Fig. 6** Impression with polyether material and picked-up Cercon Cap.  
**Fig. 7** Zirconium abutment connected to an implant analogue.  
**Fig. 8** Reseating of implant analogue/abutment unit into impression.  
**Fig. 9** Seating of zirconium ceramic abutment.  
**Fig. 10** Try-in of full-ceramic crown.  
**Fig. 11** Crown insitu immediately after cementation.

**Case report**

After osseointegration and stage-two soft tissue healing, a zirconium-dioxide abutment (Cercon, Dentsply Friadent, Mannheim) was attached to an implant (XiVE®, Dentsply Friadent, Mannheim) replacing the right lateral incisor. After placing the abutment, a premanufactured corresponding zirconium coping (Cercon Cap, Dentsply Friadent, Mannheim) was seated and an impression was taken for the fabrication of a master cast. The ceramic coping serves as an impression transfer cap, to be picked-up directly with the impression.

Before pouring the cast, the zirconium abutment was connected to an implant analogue and securely reseated into the cap. No additional modifications were required and porcelain was applied directly to the ceramic coping to complete a full-ceramic crown. The coping served as the foundation for the porcelain applied by the laboratory to create the final restoration. No additional ceramic crown or wax-up is necessary. The full ceramic crown, based on the zirconium cap, was delivered and subsequently cemented with resin cement.

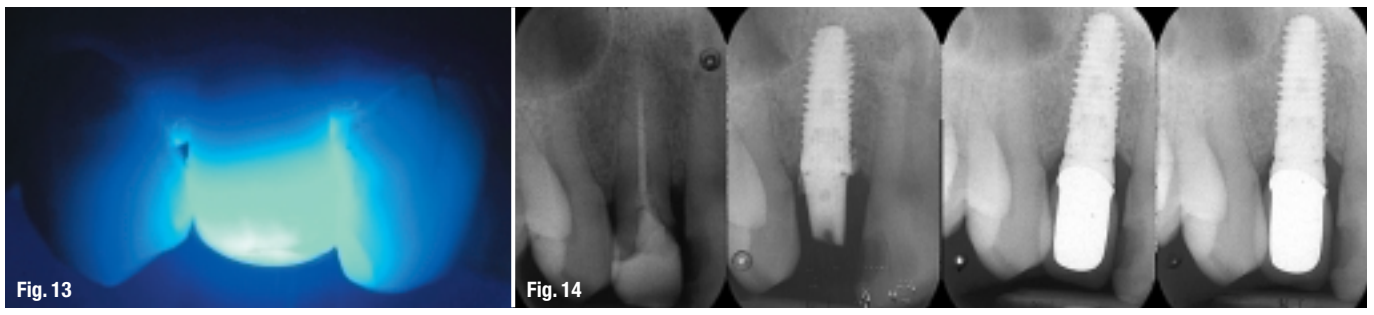**Conclusion**

The initial clinical results indicate that the investigated zirconium restorative system allows an expedited and systematic treatment to resolve esthetic challenges with a premanufactured ceramic abutment/coping system in partially edentulous patients.

*(The reference list is available from the publisher.)*

<sup>1</sup> Dr. med. dent., Private Practice, Ludwigshafen, Germany  
<sup>2</sup> M.D., D.D.S., Private Practice, Bologna, Italy, Visiting Professor University of Chieti-Pescara, Italy;

**Fig. 13:** Labial view of full-ceramic implant restoration with polymerization light. Note high translucency of restoration.  
**Fig. 14:** Treatment sequence in pre- and postoperative radiographs.



<b>_author</b>	<b>implants</b>
<p><b>Dr. Peter Gehrke</b>                  Bismarckstraße 27                  67059 Ludwigshafen                  Germany                  Phone: +49-60 21/68 12 44 56                  E-mail: dr-gehrke@dr-dhom.de</p>	