

# Modalities and Techniques of Implant Site Preparation in the Maxilla

P. SEBBAG<sup>1</sup>, P. GEHRKE<sup>2</sup>

<sup>1</sup> Private Practice, Châlons en Champagne, France

<sup>2</sup> FRIADENT, AG Mannheim, Germany

## INTRODUCTION

In order to create an ideal implant position, bone volume may be augmented or preserved prior or during stage I surgery. Therefore new sophisticated modalities of implant placement have been developed in recent years: Guided bone regeneration, a staged approach with block or particulate bone graft, and sinus lift elevation procedures. Implant placement does not follow systematically the procedures described initially by P.I. Brånemark. In the maxilla, the conventional drilling method to place an implant can advantageously be replaced by osteotome and expansion techniques. The purpose of this poster is to describe the different surgical procedures that can be performed using osteotomes or bone condensers. Conventional site preparation, ridge expansion osteotomy, future site development, and osteotome sinus lift elevation will be described and discussed.

## MATERIAL AND METHODS

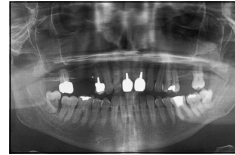
Osteotome and bone expansion techniques have been developed in recent years to optimize primary implant stability and predictable osseointegration. Because of its spongy structure and low bone density they are primarily indicated in the maxilla. Initially based on the green stick bone expansion, the osteotome technique was adapted by R.B. Summers to a precise site preparation with matching surgical instruments. A further development extended the indication to deficient alveolar ridges and limited bone height in the maxilla. The FRIALIT®-2 BoneCondenser (FRIADENT GmbH, formerly FRIATEC AG, Mannheim) are osteotomes especially designed to match the vertically tapered and stepped cylinder shape of FRIALIT®-2 implants. They allow for displacement and condensing extremely cancellous bone as well as for bone spreading techniques. The advantage of this technique is that no drilling is necessary and, consequently, overheating does not occur. Bone is not removed but relocation and densification is performed.

## CONCLUSION

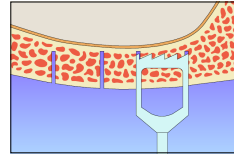
Osteotome and bone expansion techniques represent an atraumatic implant site preparation modality for the maxilla. Bone preservation, augmentation, relocation and densification can be achieved. Primary implant stability, good visibility and sense of tactility of the surgical site, simplicity and speed of implant placement, no oversized implant site preparation, and minimal postoperative complications are the advantages of these techniques. It is possible to combine these techniques with GBR procedures.

### Future Site Development Upper Left Quadrant (Site 26):

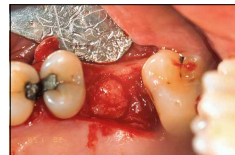If the ridge is not eligible to simultaneous implant placement a future site development technique is indicated. A bone core still connected to the membrane is prepared with a trephine bur and pushed into the sinus. The bone graft is pushed with care, gradually into the osteotomy.



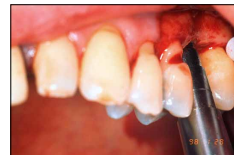Initial panoramic view: Poor bone quality, limited ridge height



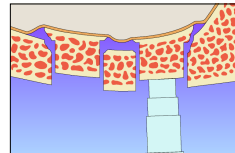
Trephine preparation



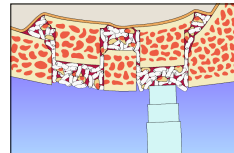
Occlusal view. Wide ridge.



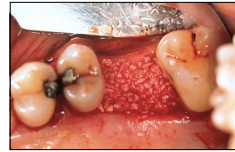Clinical condensing of bone with FRIALIT®-2 BoneCondenser



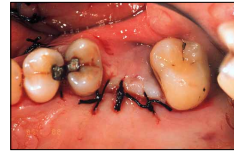
FRIALIT®-2 BoneCondenser elevating the bone core



Augmentation material placed and densified in the osteotomy



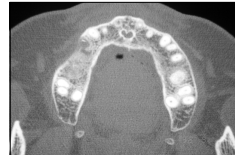Clinical view after site development



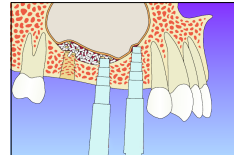
Flap sutured with primary closure

### Sinus Floor Elevation with Immediate Implant Placement: Upper Right Quadrant:

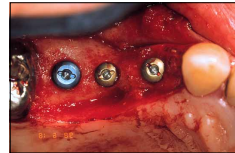
The residual ridge under the sinus presents at least 6 mm with the possibility of satisfactory primary stability. The site is shortened 1 mm to the floor of the sinus to the exact diameter. Bone grafting material is placed and pushed into the osteotomy. The floor of the sinus is infrafractured with the last instrument. The pressure is dampened by the bone graft cushion. Gradually, the sinus membrane is pushed under the pressure of the bone graft placed into the osteotomy. Implants are placed into the site prepared with the last BoneCondensers. The opening is obturated.



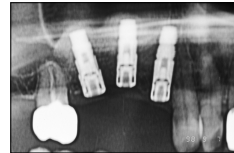Horizontal cut of CT-scan. Note the bone density in site 26



Sinus floor elevation with FRIALIT®-2 BoneCondensers



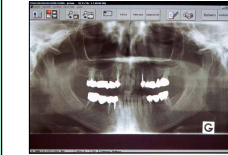Implants in place



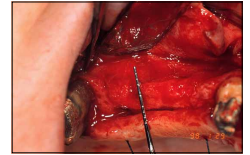
Panoramic x-ray: Bone is lifted up by implants and bone graft material

### Ridge Expansion Osteotomy with Sinus Floor Elevation and Implant Placement:


In a narrow ridge, instead of drilling and removing, bone is gradually expanded with FRIALIT®-2 BoneCondensers, preserving its thickness buccally and palatally. The implants are impacted into the osteotomy and maintain the position of the bone.



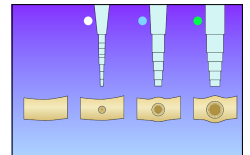
Initial panoramic view: teeth 16, 14 were hopeless and extracted



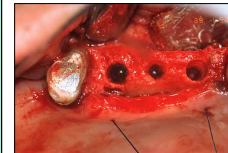
Occlusal view upper right ridge 3-6 mm wide



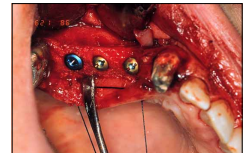
Color coded FRIALIT®-2 BoneCondenser Set



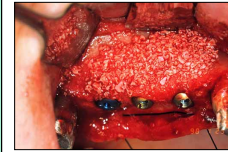
Ridge expansion with increasing size



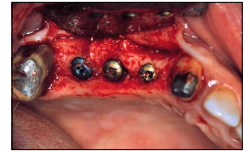
Osteotomy after ridge expansion: D 3.8 in site 14, 15/ D 4.5 in site 16



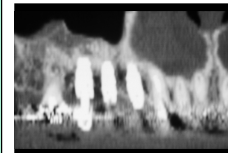
Buccal view: Implants in place after grafting of the sinus



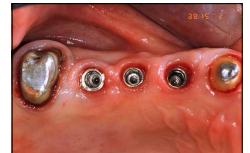Augmentation material was placed buccally



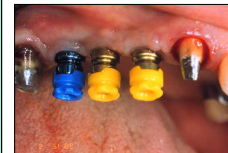Stage II surgery: Bone graft integrated and ridge expanded



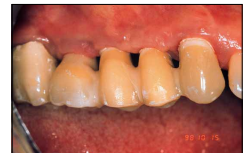Sagittal cut CT-scan: Note increased bone density and quantity



Soft-tissue healing after stage II surgery



FRIALIT®-2 impression copings and TransferCaps in place



Provisional restoration on FRIALIT®-2 ProTect abutments

### Literature:

1. **RB Summers.** A new concept in maxillary implant surgery: The osteotome technique. *Compend Contin Educ Dent*, Vol XV, No.2,4,6, Vol.XVI, 11,1994/ 1995.
2. **A Scipioni, G Bruschi, G Casellini.** The edentulous ridge expansion technique: A five-year study. *Int J Periodont Rest Dent* 1994;14:451-459.
3. **G Bruschi, A Scipioni, G Calesini, E Bruschi.** Localized management of sinus floor with simultaneous implant placement: A clinical report. *Int J Oral Maxillofac Implants* 1998;13:219-226.
4. **G Bruschi, A Scipioni, M Giargia, I Berglundh, J Lindhe.** Healing at implants with and without primary bone contact – An experimental study in dogs. *Clinical Oral Implants Research* Vol.8(1) Feb.1997.