

Prospective Evaluation of Synchronized Threaded, Grit-blasted and Acid-etched Root-analog Implants

Gehrke P.¹, Salaske I.¹,
Drücke B.², Reinhard S.²

¹ Mannheim, Germany; ² Münster, Germany



Introduction

The FRIALIT[®]-2 Synchro Stepped Screw represents a further development of the FRIALIT[®]-2 conventional stepped screw and has been available since its introduction in 1999. Its synchronized thread design and sharper thread profile offers improved self-tapping performance in dense cortical bone and less torque for seating with higher primary stability.

The surface morphology of the FRIALIT[®]-2 Synchro implant can be divided in three sections: The top has a machined collar to allow for epithelial attachment. The apical end of the collar section has a solely acid-etched microstructure for connective tissue attachment. The intraosseous section is provided with a grit-blasted and acid-etched FRIADENT DPS (Deep Profile Surface). Long term studies from Gomez et al.¹ and Krennmair et al.² reveal cumulative survival rates for all FRIALIT[®]-2 screw implants of 97% and for their prosthetic restorations of 96%. The purpose of this prospective study was to report the clinical experience and results with the FRIALIT[®]-2 Synchro Stepped Screw for single-tooth replacement and partially edentulous jaws. In addition, the incidence and the types of prosthetic complications encountered were also subjected to assessment.

Methods

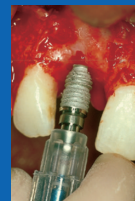

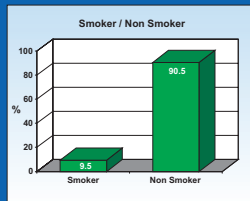
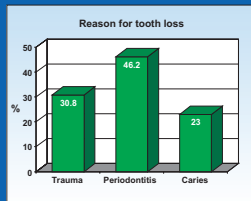
The survival rate of FRIALIT[®]-2 Synchro Screws for single tooth replacement and implant-supported bridges and related restorative problems were evaluated. 15 partially edentulous men (7) and women (8), 16 to 72 years old (mean 39 years) were recruited for this 22-month prospective clinical trial. The patients were provided with implant-supported single tooth or bridge restorations. A total of 27 FRIALIT[®]-2 Synchro implants (FRIADENT GmbH, Mannheim) were placed in the mandible and maxilla of 15 patients. Etiology of tooth loss was evaluated. Radiographs, pocket depths, plaque and bleeding indices of adjacent teeth were taken pre- and post-op. Bone quality, quantity and defect status were recorded and classified. All data of patients treated between March 1999 and February 2001 are presented.

Related Medical Concerns

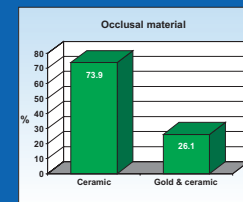
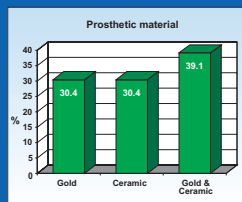
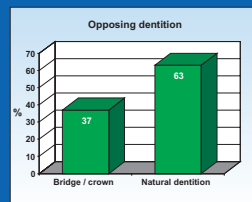
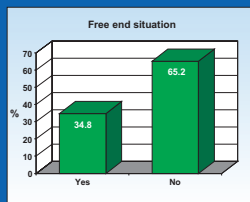
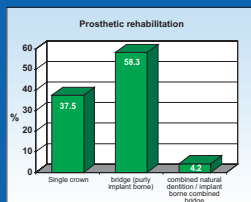
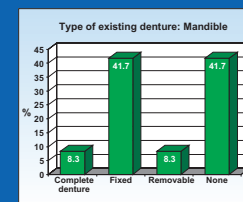
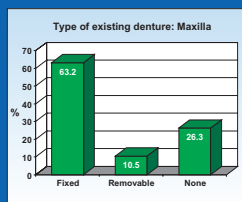
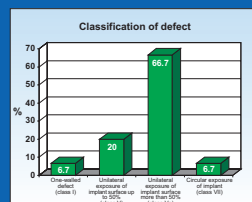
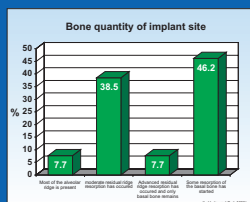
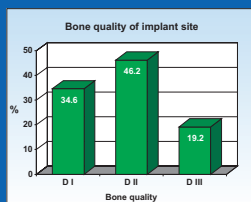
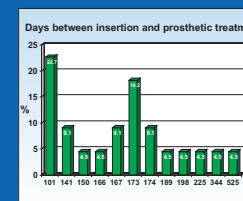
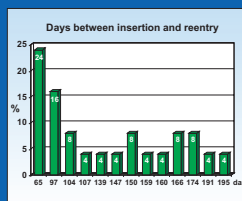
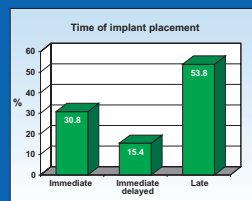
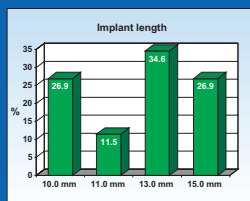
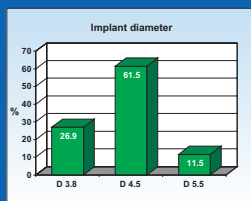
Implant Specifications and Time Frames for Treatment

Implant Site Specifications and Pre-operative Situation

Occlusion and Prosthetics



FRIADENT DPS Surface (Deep Profile Surface) / grit-blasted and acid-etched:
Structure polished area: 0.3 mm Ra 0.02 ± 0.05 Rf 4.41 ± 0.93
Solely acid-etched area: 1.1 mm Ra 0.06 ± 0.07 Rf 6.89 ± 0.93
Grit-blasted + acid-etched (below crestal part): Ra 2.22 ± 0.26 Rf 14.9 ± 2.22



Results / Conclusions

In average, 180 days (min 101/ max 525) were recorded between implant insertion and prosthetic delivery. Different prosthetic and occlusal materials (Gold/ceramic/ gold & ceramic) were used and evaluated according to the type of prosthesis. No implants failed or were removed prior to abutment connection, resulting in an overall survival rate of 100% within 22 months. Periodontal and radiographic measures demonstrate negligible loss of attachment or bone surrounding the implants up to 14 months after abutment connection. No abutment loosening or other prosthetic complications have been detected. FRIALIT[®]-2 prosthetic components compensate axial divergences in the maxilla and the internal hexagonal implant-abutment connection considerably reduces the problem of screw loosening.

Literature

- Gomez-Roman G., Kruppenbacher M., Weber H., Schulte W. Immediate protraction implant placement with root-analog stepped implants: Surgical procedure and statistical outcome after 6 years; Int J Oral Maxillofac Implants 2001;16:503-513
- Krennmair G., Schindinger S., Waldenberger O., Single-Tooth Replacement with the Frialit-2 System: A Retrospective Clinical Analysis of 146 Implants; Int J Oral Maxillofac Implants 2002;17:78-85



17th Annual Academy of Osseointegration Conference
March 14 - 16, 2002
Dallas, Texas